



PATIENT

Harley Reid

SPECIES

Feline

BREED

Ragdoll

SEX

Male Neutered

AGE

16 years

WEIGHT

12.5lbs

INTERPRETED BY

Maggie Machen Lamy,
DVM, DACVIM
(Cardiology)

IMAGING PERFORMED BY

Julia Bakker, DVM

HOSPITAL NAME

Orange Blossom
Veterinary Imaging

REFERRING VET

Dr. Neill

INVOICE

46877

DATE

2/17/26

PRESENTING CLINICAL SIGNS

History: Historic grade 4-5/6 heart murmur.

ECHOCARDIOGRAM FINDINGS

2D, m-mode, color flow and doppler imaging is available. The left ventricular wall is mildly hypertrophied. There is a mildly hyperechoic endocardium consistent with fibrosis and ventricular remodeling. Mild papillary muscle remodeling. The right ventricle is subjectively normal in size and morphology. There no left atrial enlargement present. No right atrial enlargement present. Normal RVOT velocity. Systolic anterior motion (SAM) of the mitral valve is present, with an elevated dynamic LVOT velocity. There is mild eccentric mitral regurgitation present secondary to SAM. No other significant valvular regurgitation is present. There is no pericardial effusion noted. No pleural effusion appreciated. No obvious cardiac tumors.

CARDIAC CHART

FELINE CARDIAC PARAMETERS	BODY WEIGHT (kg)	HR (BPM)	IVSd (cm) <small>(Moise, Pipers)</small>	LVIDd (cm) <small>(Moise, Pipers)</small>	LVWd (cm) <small>(Moise, Pipers)</small>	FS (%)	EF (%)
NORMAL PARAMETER	-----	150-240	0.35-0.55	<2 (mean 1.5)	3.5-0.55	35-67	80-100
PATIENT	5.7	NM	0.66	1.2	0.67	52	90
FELINE CARDIAC PARAMETERS	LA/AO <small>(Boon)</small>	LA/AO HEART BASE <small>(Swe) (Abbott)</small>	LA 2D short axis Base view (cm) <small>(Abbott)</small>	LVOT VEL (m/s)	RVOT VEL (m/s)	E max (m/s)	
NORMAL	<1.5	<1.3	<1.2	<1.6	<1.3	<0.9	
PATIENT	1.3	1.4	1.2	>4.0	1.0	NM	

**Note: All measurements based upon multi-modal images and methods. An average value is reported.
Adapted from June Boon, Veterinary Echocardiography, 1998
Abbott J & MacLean H JVIM 2006;20: 111-119, Moise et al. Am J Vet Res 47:1476, 1986. Pipers et al. Am J Vet Res 40:882, 1979.*

INTERPRETATION OF THE FINDINGS & FURTHER RECOMMENDATIONS

The diagnosis is hypertrophic obstructive cardiomyopathy (HOCM). This indicates LV thickening (mild in this case) with a dynamic LVOT obstruction (SAM) and secondary mitral regurgitation as the cause of the heart murmur. The hypertrophy and obstruction are both mild. There is no left atrial enlargement present, indicating the risk of spontaneous CHF and/or a thrombotic event is currently low. No additional issues are identified.

While no medications have been shown to definitively alter long term outcome at this stage of disease, atenolol is often initiated to decrease the outflow obstruction. If the patient is easily medicated, it may be reasonable to initiate at this time as below. If there is difficulty medicating at home, an alternative approach would be to monitor for progression over the next 6-12 months. Discussion with the owner is advised. No additional medications are indicated prior to significant atrial dilation. *Regarding the newly available drug Felycin:* This medication has not



PATIENT

Harley Reid

SPECIES

Feline

BREED

Ragdoll

SEX

Male Neutered

AGE

16 years

WEIGHT

12.5lbs

INTERPRETED BY

Maggie Machen Lamy,
DVM, DACVIM
(Cardiology)

IMAGING PERFORMED BY

Julia Bakker, DVM

HOSPITAL NAME

Orange Blossom
Veterinary Imaging

REFERRING VET

Dr. Neill

INVOICE

46877

DATE

2/17/26

been tested in cats with a significant obstruction (i.e. HOCM) and is not recommended in this case.

Long term prognosis is guarded for subclinical HOCM, with a great deal of variability in rate of progression. The REVEAL study showed that approximately 7% of asymptomatic cats with HOCM will develop CHF or a cardiogenic thrombus within 1 year, 20% within 5 years, and ~30% within 10 years. Close monitoring for progressive LA dilation going forward will help better predict long term outcome.

Monitor at home for any respiratory signs or blood clot events (neurologic change, paralysis, etc.).

Anesthetic risk is considered mild; however, judicious fluid administration is advised if needed with careful monitoring to screen for fluid overload. A reasonable protocol includes opioid/benzodiazepine premedication, propofol induction, isoflurane maintenance. Avoid ketamine, telazol, acepromazine and Dexdomitor. Additionally, drugs that stimulate heart rate should be avoided unless clinically necessary (glycopyrrolate, atropine).

Risk for complication with steroid or fluid use typically follows LA dilation, which in this case is low. That said, any cat can experience acute intolerance and monitoring for this phenomenon is always advised (a change in RR/RE, particularly during the initiation phase).

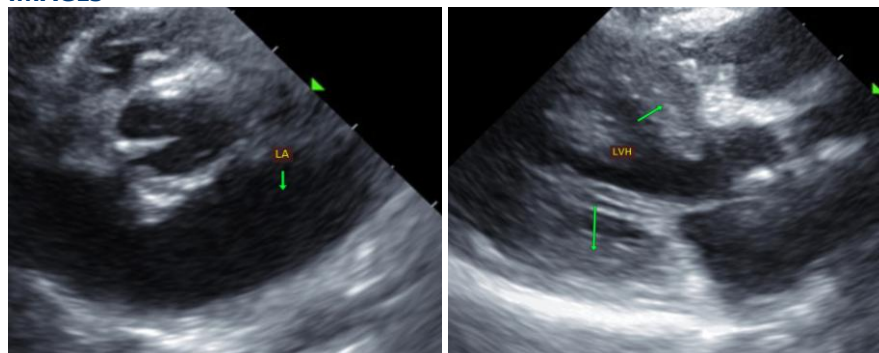
PLAN

If elected/able, administer titrating dose of atenolol: 25mg tablets; Give ¼ tab once daily. Recheck heart rate in 1-2 weeks with target stressed rate of 140-160bpm 12-24 hours post-administration. Increase as needed until target reached.

Screening blood pressure and T4 are recommended every 6 months.

Recommend recheck echocardiogram in 6-12 months to assess for progression, sooner if clinical issues arise.

IMAGES





PATIENT

Harley Reid

SPECIES

Feline

BREED

Ragdoll

SEX

Male Neutered

AGE

16 years

WEIGHT

12.5lbs

INTERPRETED BY

Maggie Machen Lamy,
DVM, DACVIM
(Cardiology)

IMAGING PERFORMED BY

Julia Bakker, DVM

HOSPITAL NAME

Orange Blossom
Veterinary Imaging

REFERRING VET

Dr. Neill

INVOICE

46877

DATE

2/17/26

The information and recommendations provided are based on the images presented by the referring veterinarian. No evaluation can be communicated regarding pathology that was not visible in the image/video clips provided.

Thank you for this referral. This report was generated using transcription software, and minor dictation errors may be present. If the clinical or image interpretation does not parallel your findings or if I can be of any further assistance, please contact me.

Maggie Machen Lamy, DVM

Diplomate of the American College of Veterinary Internal Medicine (Cardiology)

info@sonopath.com